

Anatomy & Physiology of the Heart

The heart is a pump, which propels blood through the body. It weighs less than a pound, is about six inches in length and lies point downward in the chest cavity to the left of the mid-center bodyline. The walls of the heart are made entirely of muscle; within these walls are four hollow chambers, a left and right receiving chamber (atrium) and left and right pump chamber (ventricle).

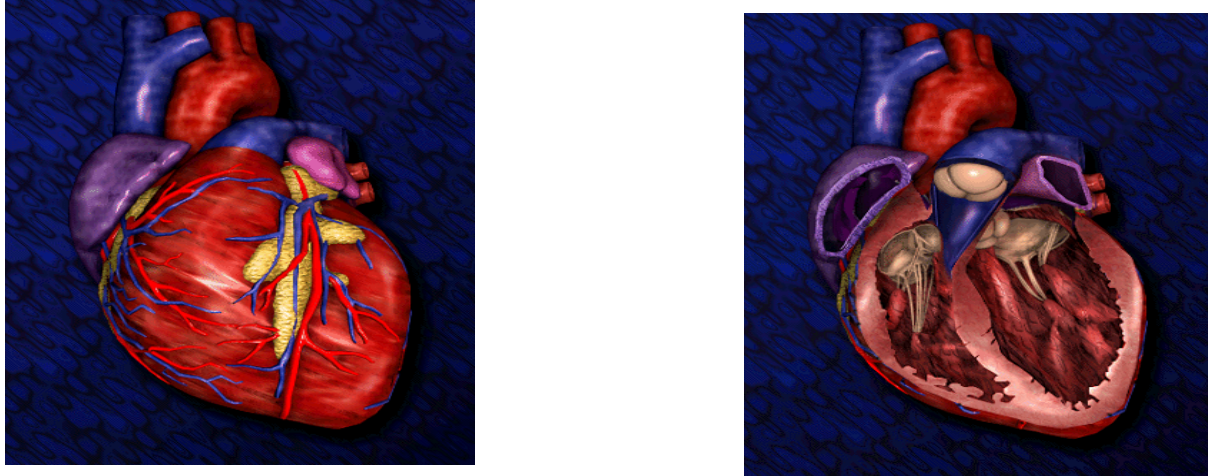


Figure 1.

As a muscle the heart lies both physiologically and anatomically between the striated voluntary muscle such as skeletal muscles and smooth involuntary muscle such as intestinal muscle. Heart muscle is striated like skeletal muscle. In a skeletal muscle though the structure is such that the initiation of an action potential in a muscle fiber would result in it being confined to that fiber; other muscle fibers would remain inactive. The anatomy of cardiac muscle is such however that the initiation of an action potential in a fiber would result in the action potential excitation of all the muscle fibers. The heart muscle also differs from skeletal muscle by being self-excitatory, i.e., its muscle fibers can generate an action potential without any nerve signal inputs. In this respect it is like smooth muscle. Although any portion of the heart can generate an action potential, a specialized portion of the heart called the SA (Sino-Atrial) node generally initiates a heart beat. This is a small strip (3 mm wide by 1 cm long) of muscle located in the right atrium where the vena cava terminates. The resting potential of a SA muscle fiber is low (-60 mV) presumably due to the high g_{Na} .

This high g_{Na} causes leakage of Na across the membrane causing depolarization. The self-depolarization of the SA node generates a rhythmic series of action potentials. These action potentials then spread throughout the right and left atrium causing the atrium to contract and pump blood into ventricles (diastole). The action potential propagates through the atria at a relatively slow velocity (0.3-0.4 m/s). From the atrium the action potentials propagate to the AV (Atrioventricular) node, a pathway of muscle fiber, which conduct the action potentials to the ventricles. A delay of about 11 ms is encountered here allowing time for the atria to pump blood into the ventricles.

From the AV node the action potential propagate via the bundle of His and the Purkinje fibers to the myocardium (muscles) comprising the ventricles. The bundles of His and Purkinje fibers are themselves large muscle fibers whose action potentials propagate at a velocity of 1.5-2 m/s. Compared to nerve and skeletal action potentials the heart's action potential has a plateau during which the muscle fiber is depolarized. This plateau allows the muscle fibers to contract in synchronism resulting in a forceful pumping action. The ECG signal, picked up by the surface electrode on the body surface is a superposition of these action potentials.

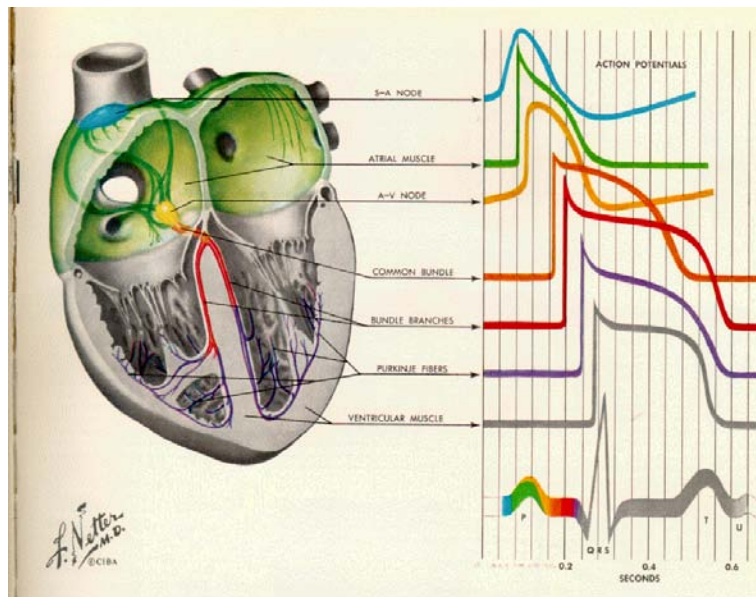


Figure 2.

Although the SA and AV nodes (and also atrial node and ventricular muscles) have pacemaker potential, the SA node is the normal cardiac pacemaker because it depolarizes at a faster rate than the rest of the conduction system (60-100 beats/min). The AV node rate is about 40-60 beats/min in the absence of the SA node function and the ventricular muscle rate in the absence of the others is 20-40 beats/min. Therefore, these can act like a backup if any thing happens to the SA node.

A typical ECG signal is shown in the following figure.

- P waves signal comes from depolarization of the atria.
- QRS is the depolarization of the ventricle.
- T and U waves arise from ventricular repolarization.

In most ECG's you won't see a U wave at all. While U waves are unusual, they are not necessarily abnormal. U waves are common in sinus bradycardia (a slow heart rate). Prominent U waves may, however, reflect an abnormality (such as hypokalemia or hypotheermia), so it is a good idea to notice if they are present.

The PR interval has clinical significance as during the PR interval four things happen:

1. A wave of depolarization sweeps over the atrium (this generates P wave);
2. When the atrial wave gets to the AV node, activates it.
3. The AV node conducts the impulse slowly to the ventricular conduction system, delaying it.
4. The ventricular conduction system conducts the impulse quickly to the endocardium.

The PR interval is normally between 0.12-0.21 seconds. Longer PR intervals suggest slowing of AV node function and shorter PR intervals suggest an unusual conduction mechanism.

The QT interval defines the total duration of ventricular depolarization and repolarization. The QT interval can be prolonged in various toxic and metabolic states. The QT interval is a function of heart rate: as the heart rate increases both QT and TP must decrease.

A normal QRS complex lasts up to 0.1 seconds. The prolonged QRS is a sign of abnormality. Some very abnormal QRS complexes can last up to 0.2 seconds, although most of abnormal cases last 0.1-0.16 seconds.

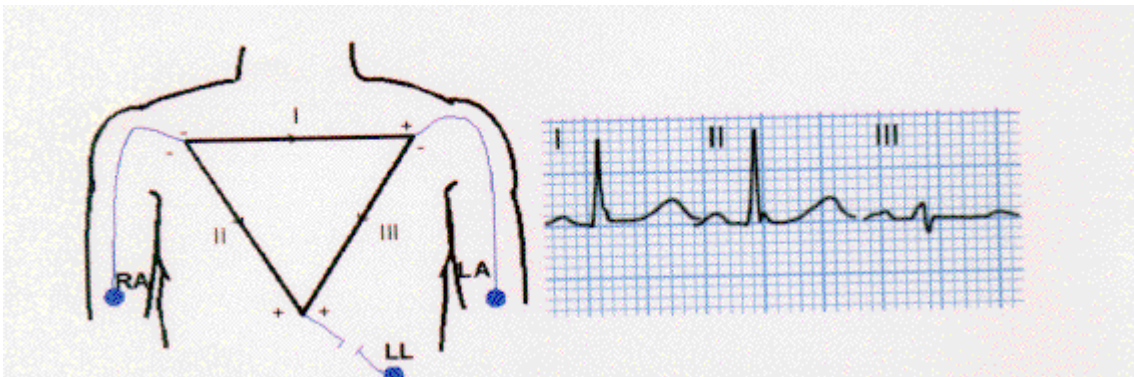
Heart as a Dipole

The electrical activity of the heart can be represented by considering the heart to be an electrical generator enclosed in a volume conductor. This generator is usually chosen to be a dipole (voltage or current) located at some fixed point which is chosen according to mathematical, physical or purely intuitive principles. The dipole moment is represented by a vector P , which during depolarization and repolarization will vary in magnitude and direction.

In electrocardiography a lead is defined as a combination of at least two electrodes sometimes interconnected with weighting resistors or operational amplifiers in such a way that a potential difference is developed in a recording system. The potential difference, v_{ij} , in any particular lead is the projection of the heart vector into that particular lead.

Clinically 12 leads are used. The first three leads are defined by Einthoven's triangle:

Lead I = LA-RA



Lead II = LL-RA

Lead III = LL-LA

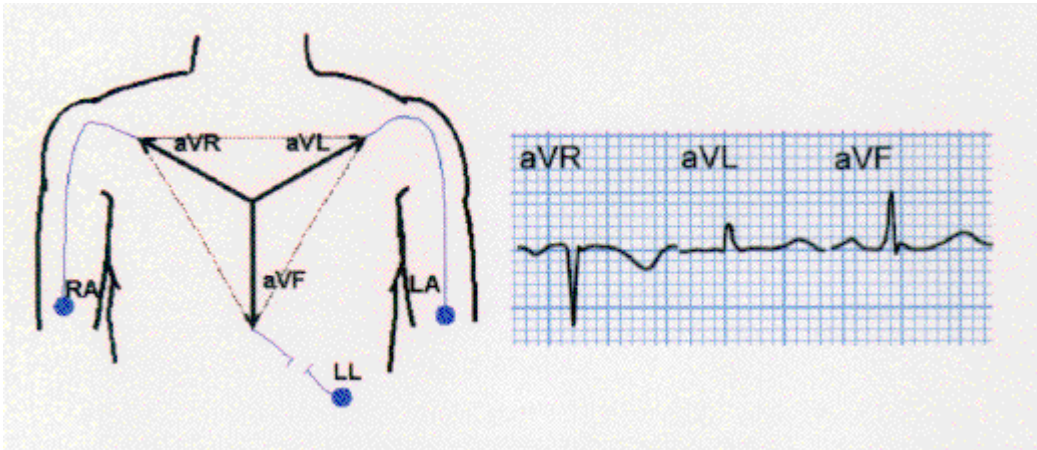
Since the voltages recorded in the leads are considered to be projections of the cardiac vector on the particular lead, any two of the leads may be used to plot the instantaneous magnitude and direction of the cardiac vector in the frontal plane. This leads to vectorcardiography, a technique that really presents another way of looking at the heart's electrical activity.

Einthoven's triangle was based on a human torso, which was triangular in shape and homogeneous. The human body is neither triangular nor homogeneous. This distorts the surface potentials leading to a cardiac vector which is in error when deduced from Einthoven's triangle. However, clinical interpretation of ECG's is quite empirical in practice, cardiologists still prefer Einthoven's approach as opposed to the other proposed models that considered the inhomogeneities of the lungs and spine.

The next three leads are the augmented or unipolar leads. aV_R , aV_L , aV_F , which are derived from electrodes connected as shown below.

It can be easily proven that

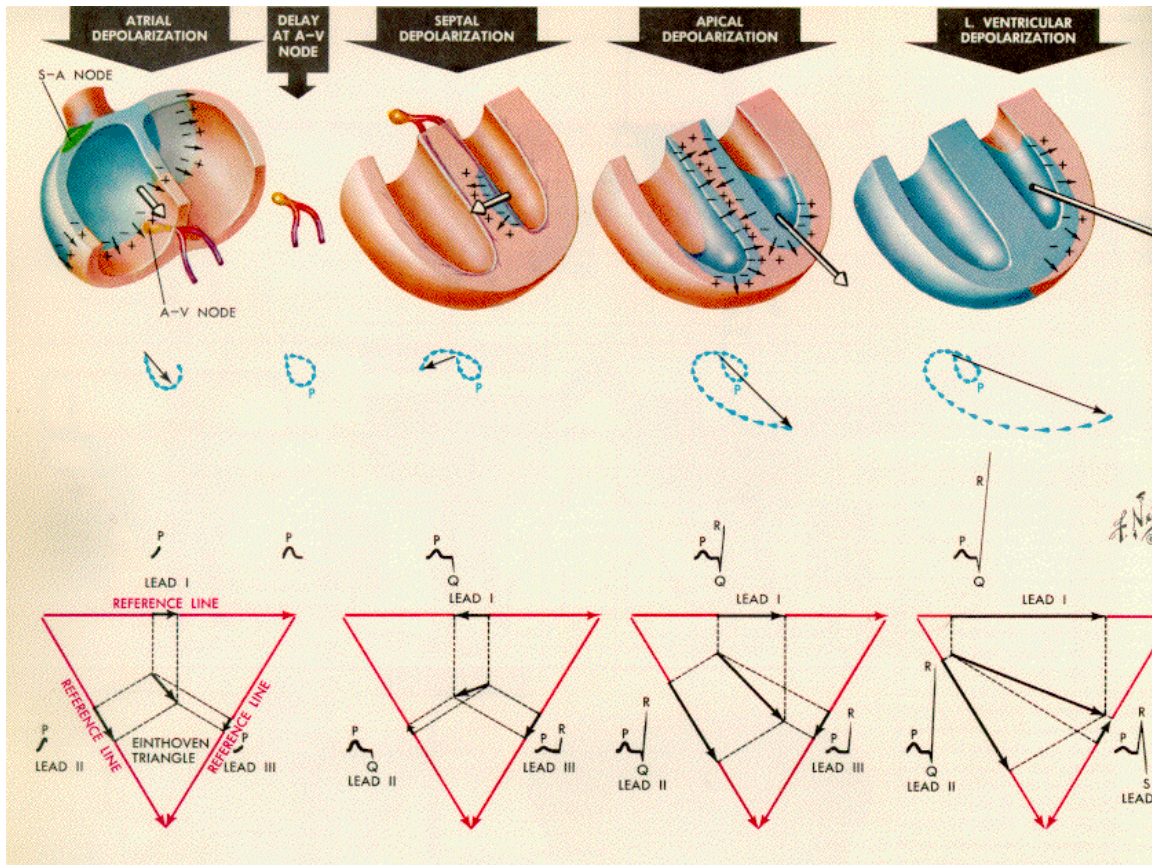
$$aV_R = -\frac{V_I + V_{II}}{2}, \quad aV_L = \frac{V_I - V_{III}}{2} \quad \text{and} \quad aV_F = \frac{V_{II} + V_{III}}{2}$$

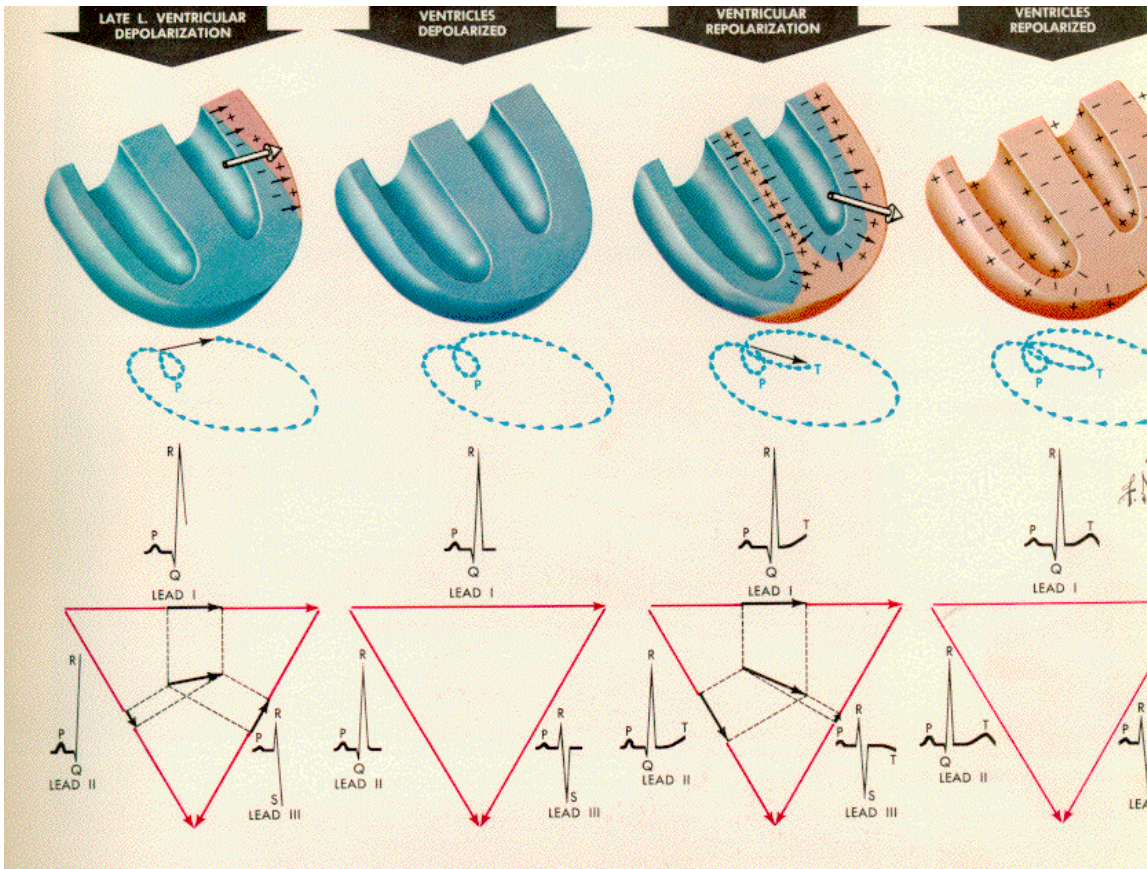


Note that all three of the initial limb leads are directed either down or to the left. In the normal example, Leads I, II, and III all show a QRS that is primarily positive. You may correctly conclude that the normal depolarization wave travels to the left and down.

By adding these three new leads, we now have the six standard electrocardiographic leads: I, II, III, aVR, aVL, and aVF. These standard limb leads give a fairly complete picture of the direction of depolarization in the frontal plane. Note that Einthoven's picture now describes a series of directions at 30 degree intervals:

The change of cardiac vector based on the dipole theory of the Einthoven is shown in figures below.





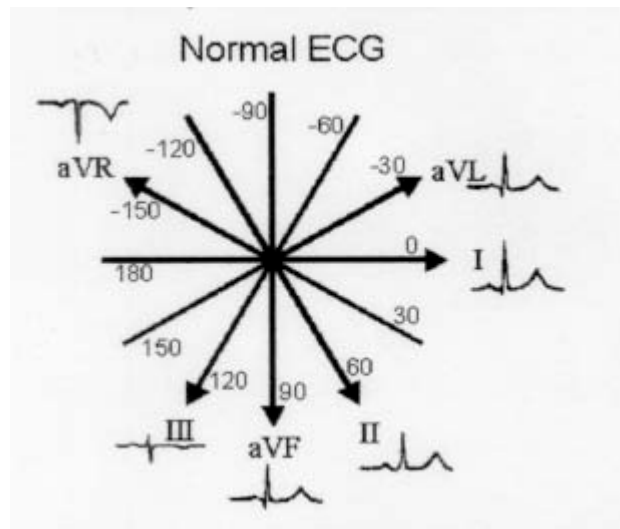
If one has the recording of two limb leads, then with little calculation can plot the vectorcardiograph of the heart. However, clinicians rather to look at the 6 or 12 lead recording and eyeballing the axis of the QRS complex. Note that leads II, III and aVF are all clustered near one another. These are called the inferior leads, for obvious reasons. These leads tell you about abnormalities in the inferior wall of the heart.

Each wave has an axis. In theory, one can describe an axis for any point in the ECG, and axes are most often calculated for the P wave, the QRS complex, and the T wave. The P wave axis is used to figure out if the atrial depolarization originated in the SA node. If the P wave is upright in the leads I and F, then the atrial depolarization is moving down and to the left, and this is usually taken as an indication that P is a "sinus P", which is normal.

The T wave axis is normally similar to the QRS axis (within 30-60 degrees). The axis of the ECG or heart is generally used to refer to the axis of the QRS complex. To find the axis:

1. Look for an isoelectric lead (equally up and down or no net deflection).
2. Find the lead perpendicular to the isoelectric lead.
3. If the QRS in the perpendicular lead is upright, the axis is in the same direction as the perpendicular lead.
4. If the QRS in the perpendicular lead is inverted, the axis is opposite the perpendicular lead.

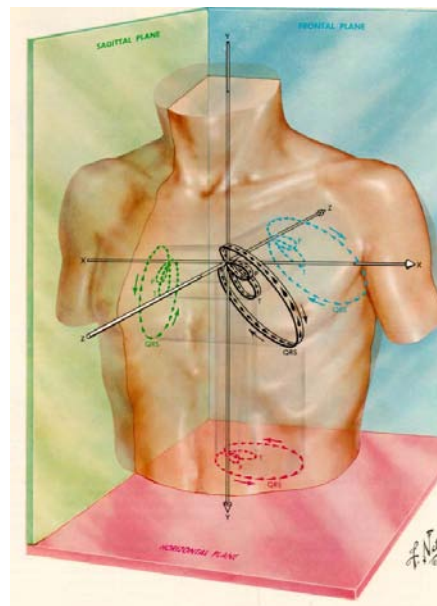
The normal range for the axis of the ECG is within -30 to 110 degrees.



Precordial Leads

Since the heart is not placed parallel to frontal plane, therefore the frontal leads give information about the inferior and lateral walls but don't distinguish between septal and anterior and lateral walls of the heart. Therefore, the vectorcardiograph should be looked at both frontal and horizontal planes. The figure below shows the three anatomical planes.

In addition to the 6 frontal leads, 6 other leads on the chest are also commonly used. Chest leads are commonly called "precordial" (in front of the heart) leads. The standard chest leads are labeled V1 through V6.



These leads tell about the distribution of disease across the anterior wall of the left ventricle but don't help with inferior wall disease. The following figure shows all the 12 leads and their ECG signal.

